CONGRÈS Cœur et Sport
PAU
Palais Beaumont
19ème ÉDITION
Organisé par le CLUB DES CARDIOLOGUES DU SPORT
www.congres-coeur-et-sport.com
9/10 mai 2019

Cherchez les coronaires !

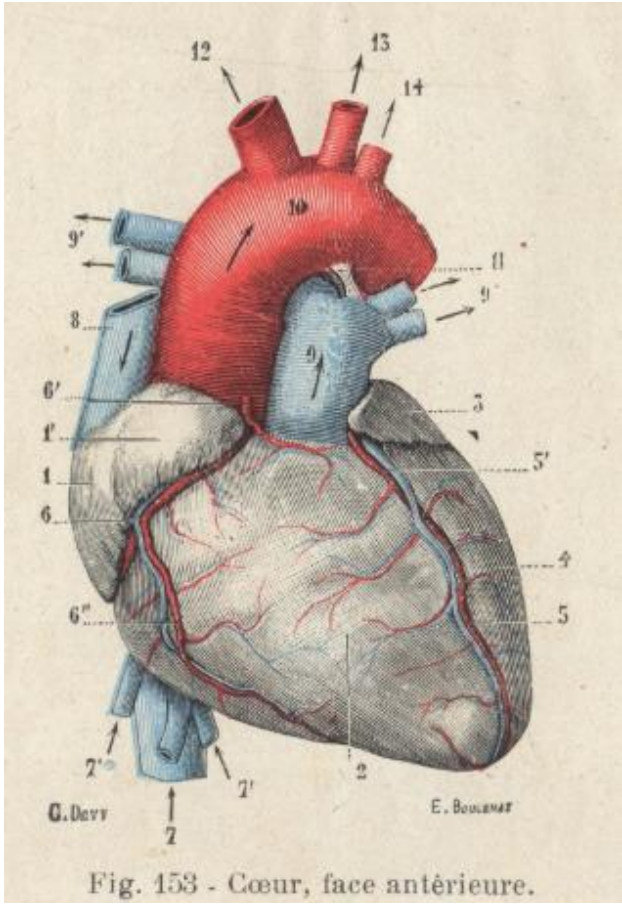

Fig. 153 - Cœur, face antérieure.

Frédéric Chagué

Pau 9/05/2019

Étiologies de la mort subite chez le sportif

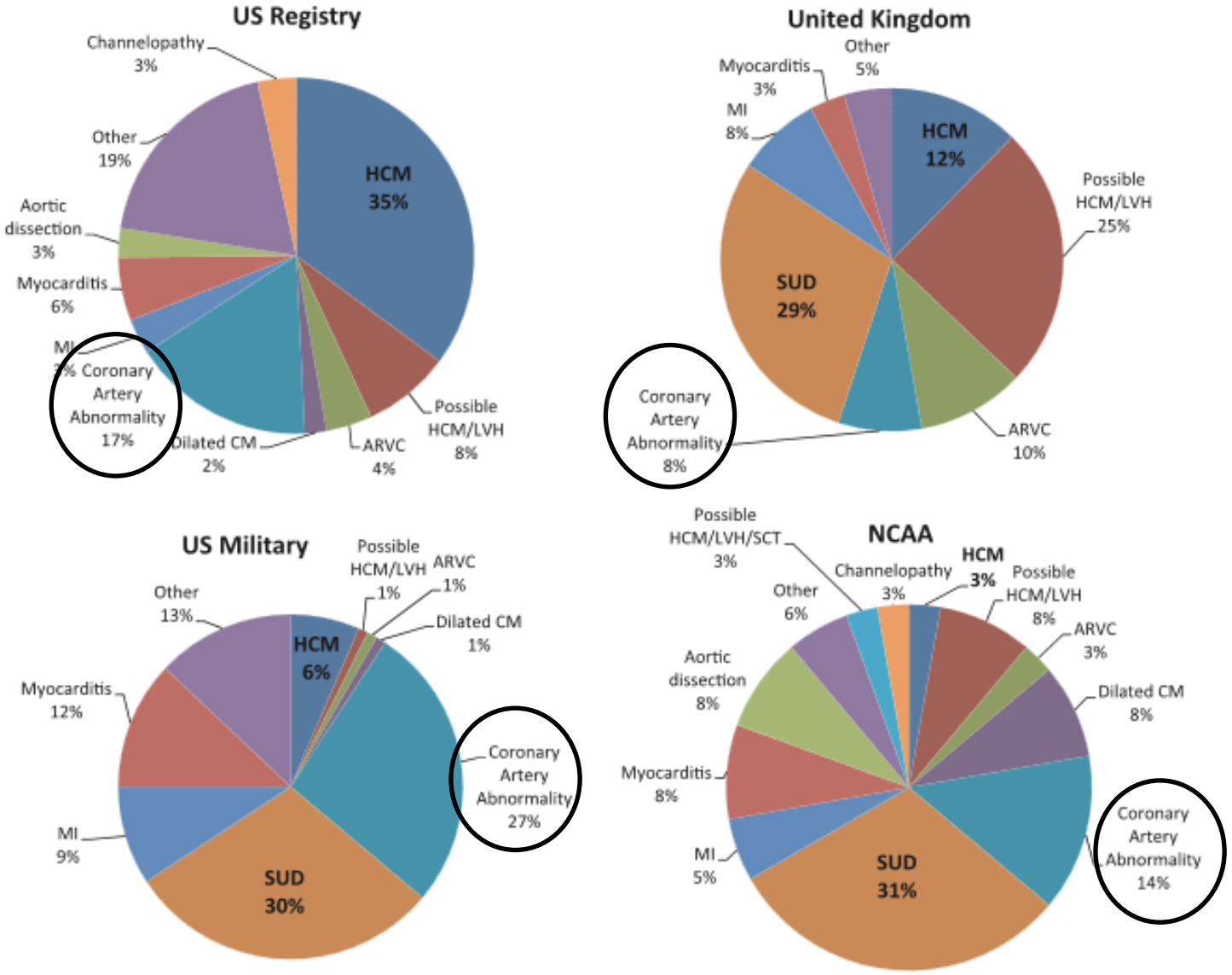

Harmon K. et al Circ Arrhythm Electrophysiol. 2014; 7: 198-204.

Risque des ANOCOR à l'effort

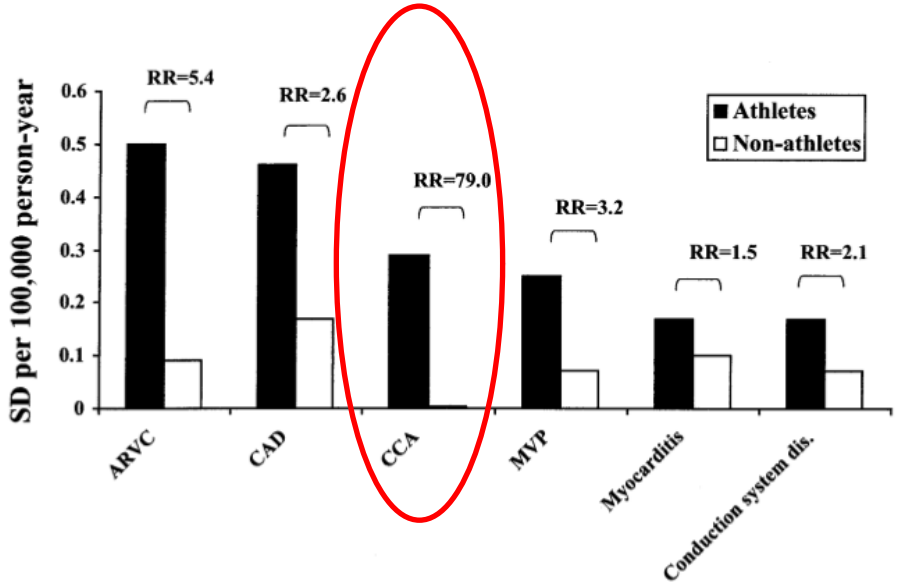

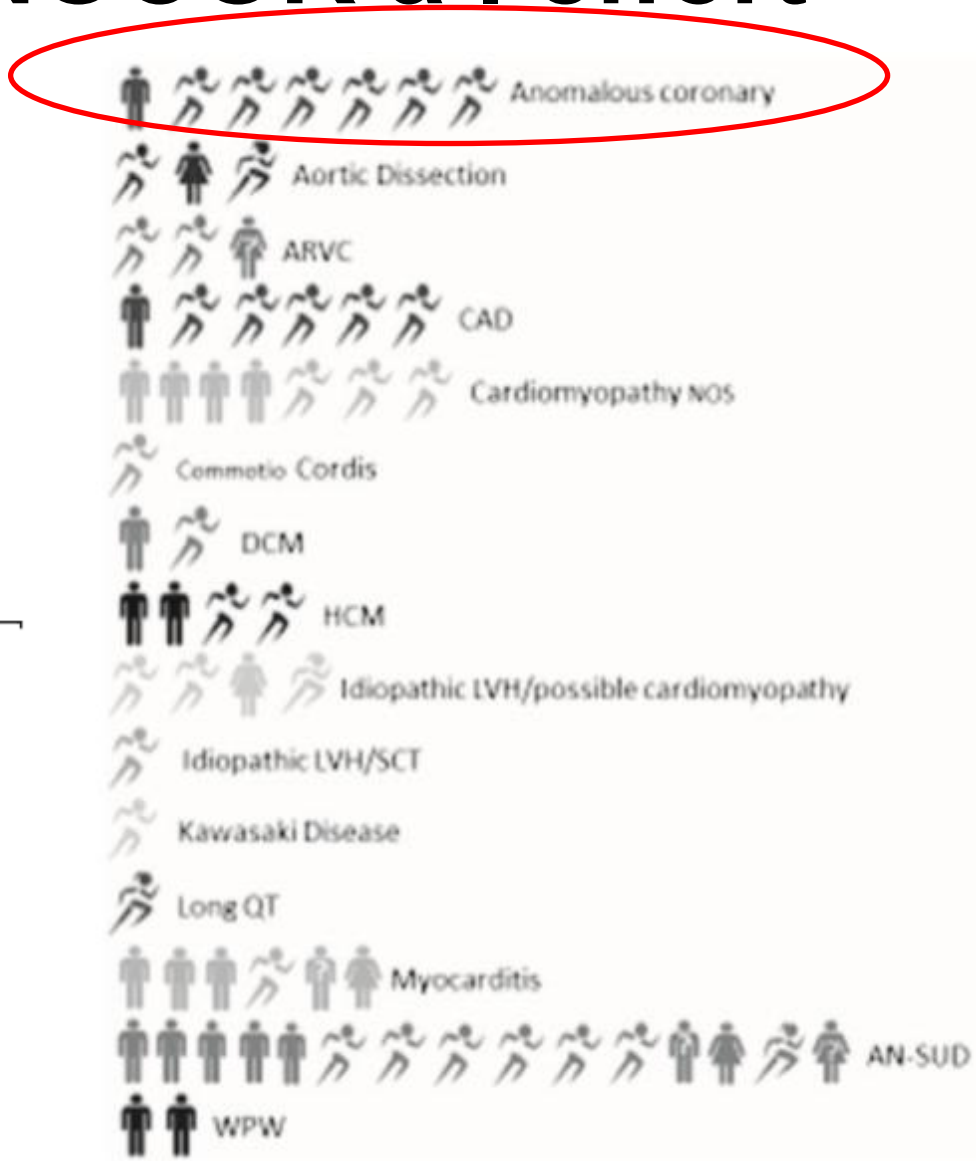

Corrado D et al. J Am Coll Cardiol. 2003; 42:49-53.

Harmon K et al. Circulation. 2015; 132: 10-19.

Séries autopsiques

- Jeune âge,
- Coronaire gauche,
- Naissance à angle fermé,
- Trajet inter-artériel
- Trajet intra-mural
- Décès souvent subit
- Surtout à l’effort (ou post-effort)
- Prodromes fréquents
- Certains avaient bénéficié d’un test d’effort (négatif)

Taylor AJ et al. J Am Coll Cardiol. 1992; 20: 640-7.
Eckart RE et al. Arch Intern Med. 2004; 141: 829-34.
Basso C et al. J Am Coll Cardiol. 2000; 35: 1493-501.

Classification des ANOCOR

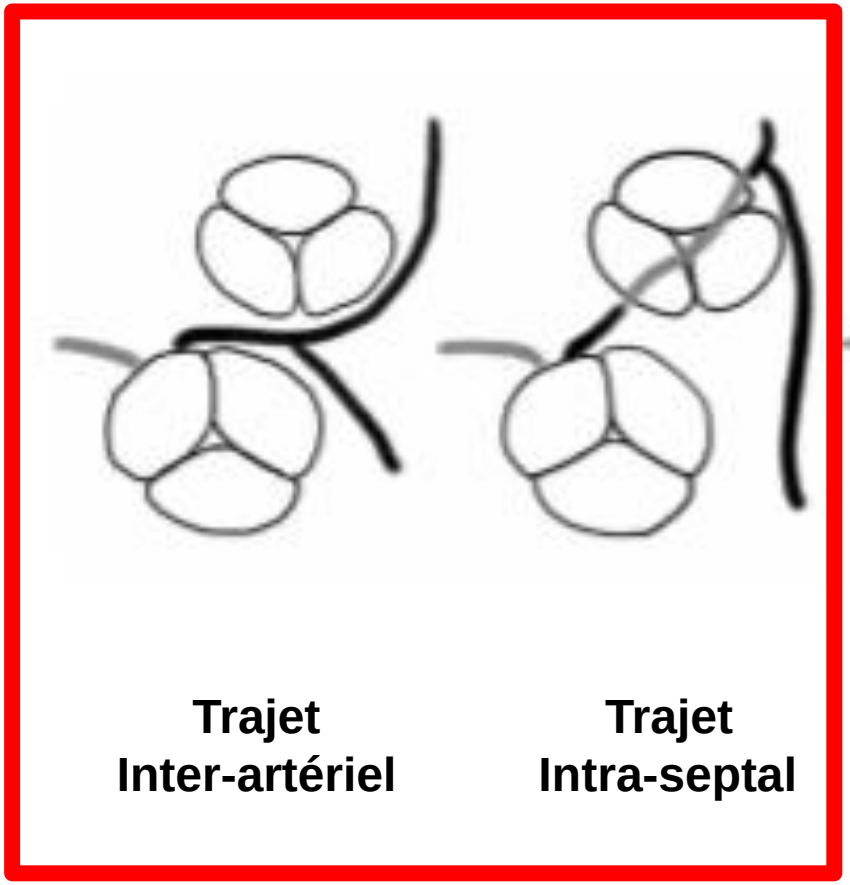

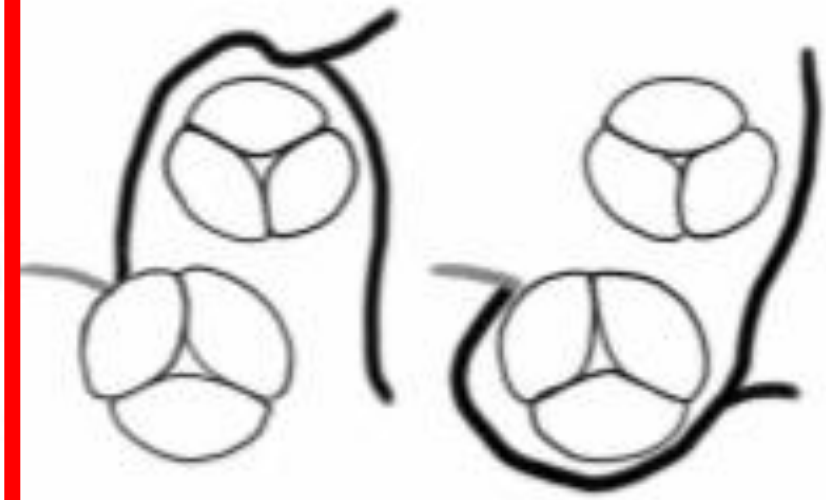

Adapté d'après Raimondi F et Bonnet D.
Journal de Radiologie diagnostique et Interventionnelle 2016 ; 97 : 195-203

Types d'ANOCOR

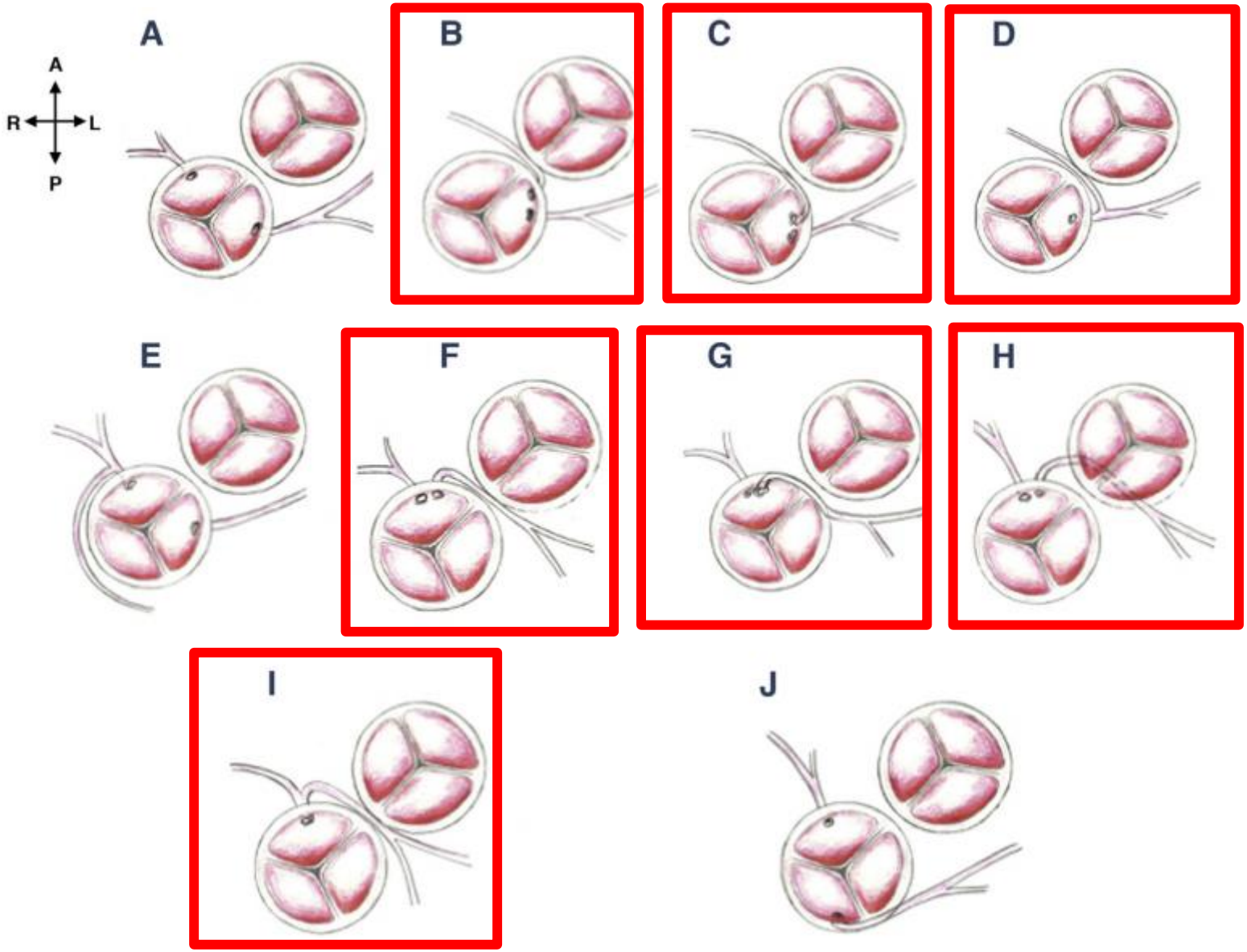

D'après Lorber R et al. J Am Coll Cardiol Img. 2015; 8: 1239-49.

Prévalence dans la population

- **Grandes disparités**
  - Population étudiée
  - Examen utilisé
  - Expérience de l’opérateur

- **Anomalies à risque** : naissance dans le sinus opposé avec **trajet inter-artériel = 0,4%**

Cheezum MK et al. J Am Coll Cardiol. 2017; 69: 1592-608.

Aubry P et al. Ann Cardiol Angéiol. 2017 ; 66 : 309-318.

Angelini P et al. Tex Heart Inst J. 2018; 45: 205-13.

Mécanismes impliqués

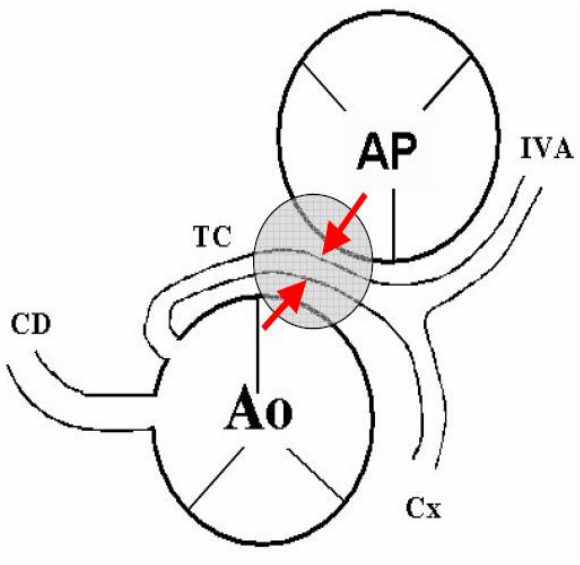

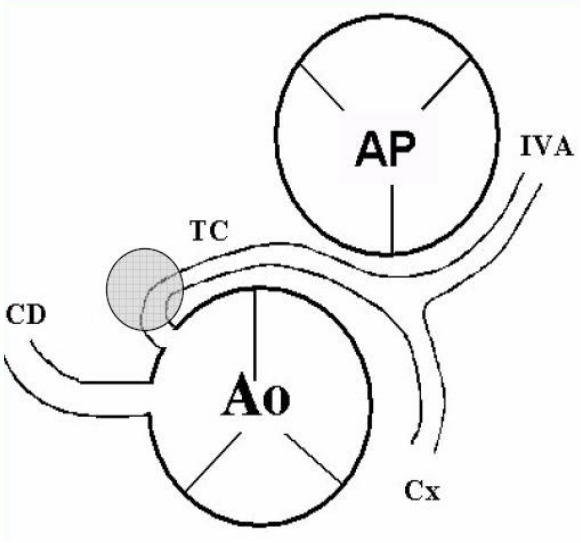

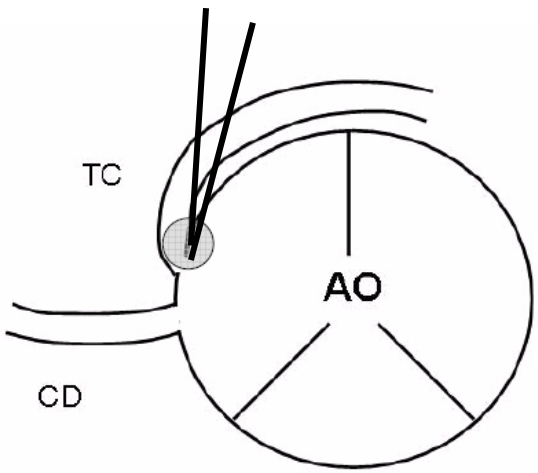

Mécanismes impliqués

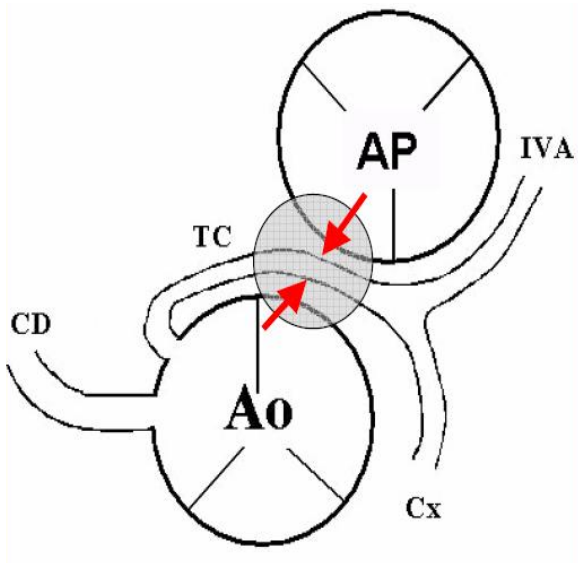

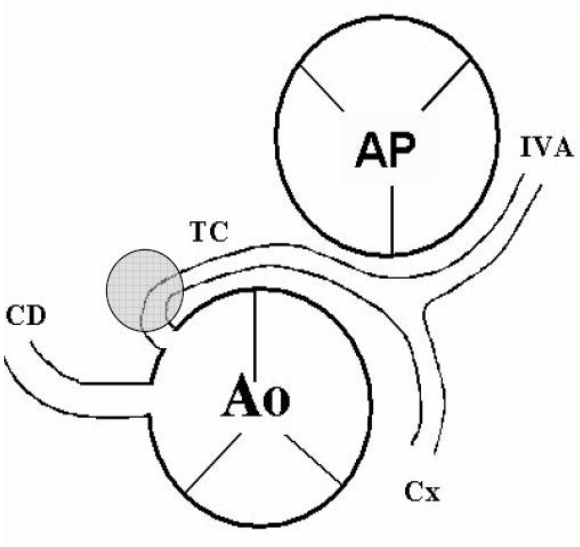

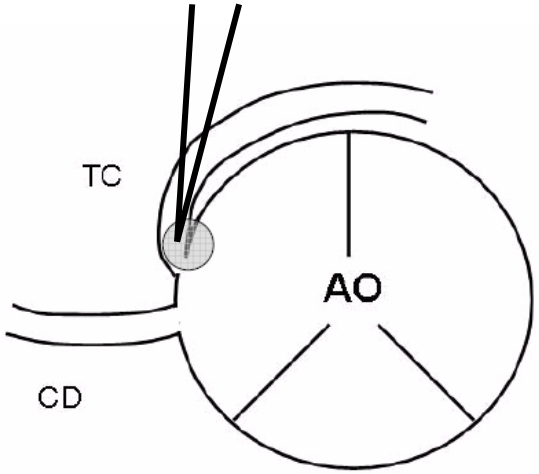

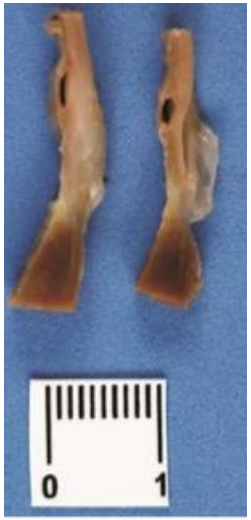

Mécanismes impliqués

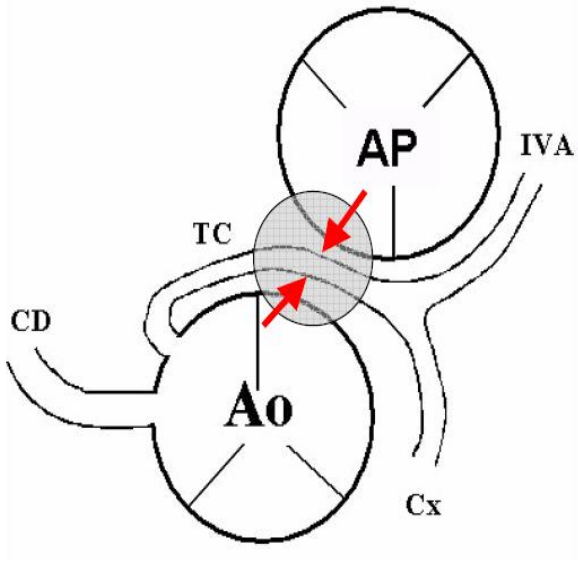

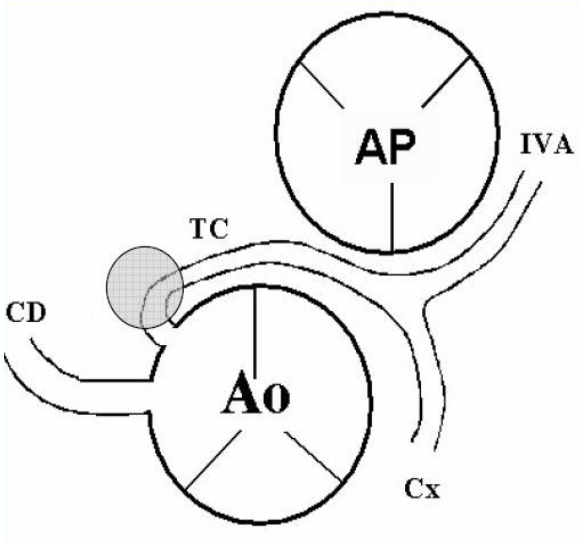

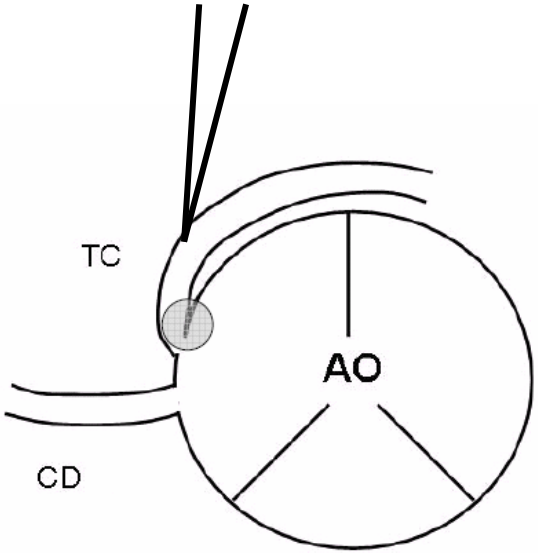

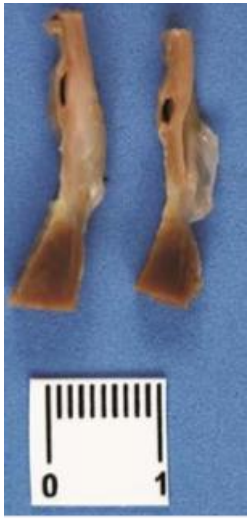

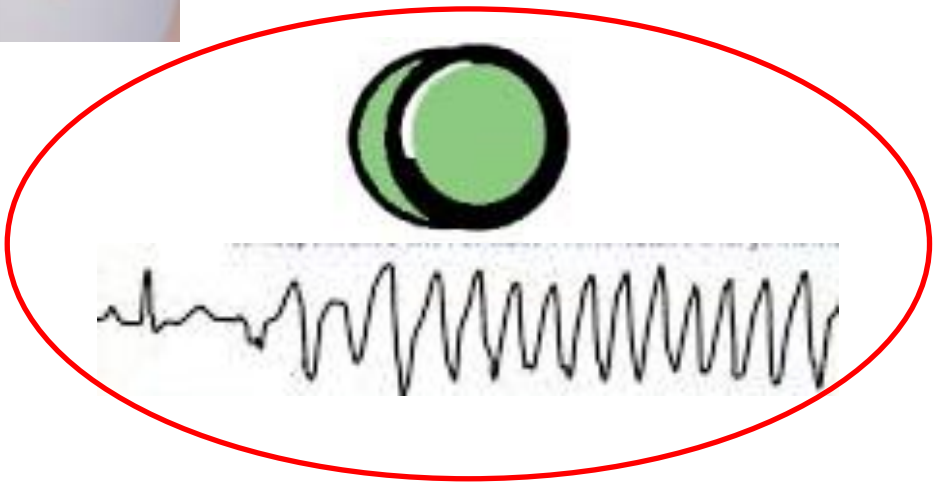

Comment chercher les ANOCOR

- **Différentes situations**
  - Screening
  - Symptômes…
  - Tests d’ischémie positif…

Comment chercher les ANOCOR

- **Différentes situations**
  - Screening
  - Symptômes…
  - Tests d'ischémie positif…

- **Examens morphologiques**

  - Échocardiographie+++
    Images dans plus de 90% des cas
  - Coroscanner
  - IRM

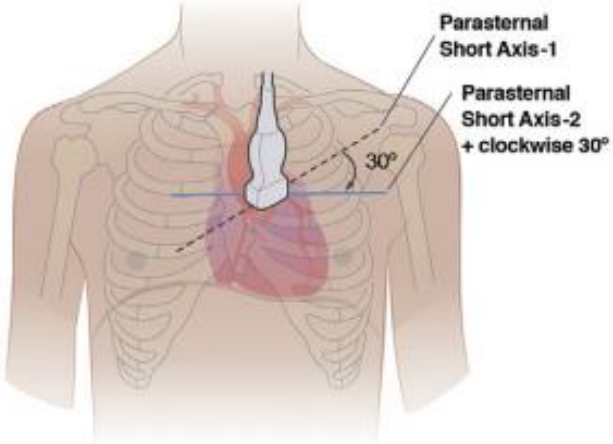

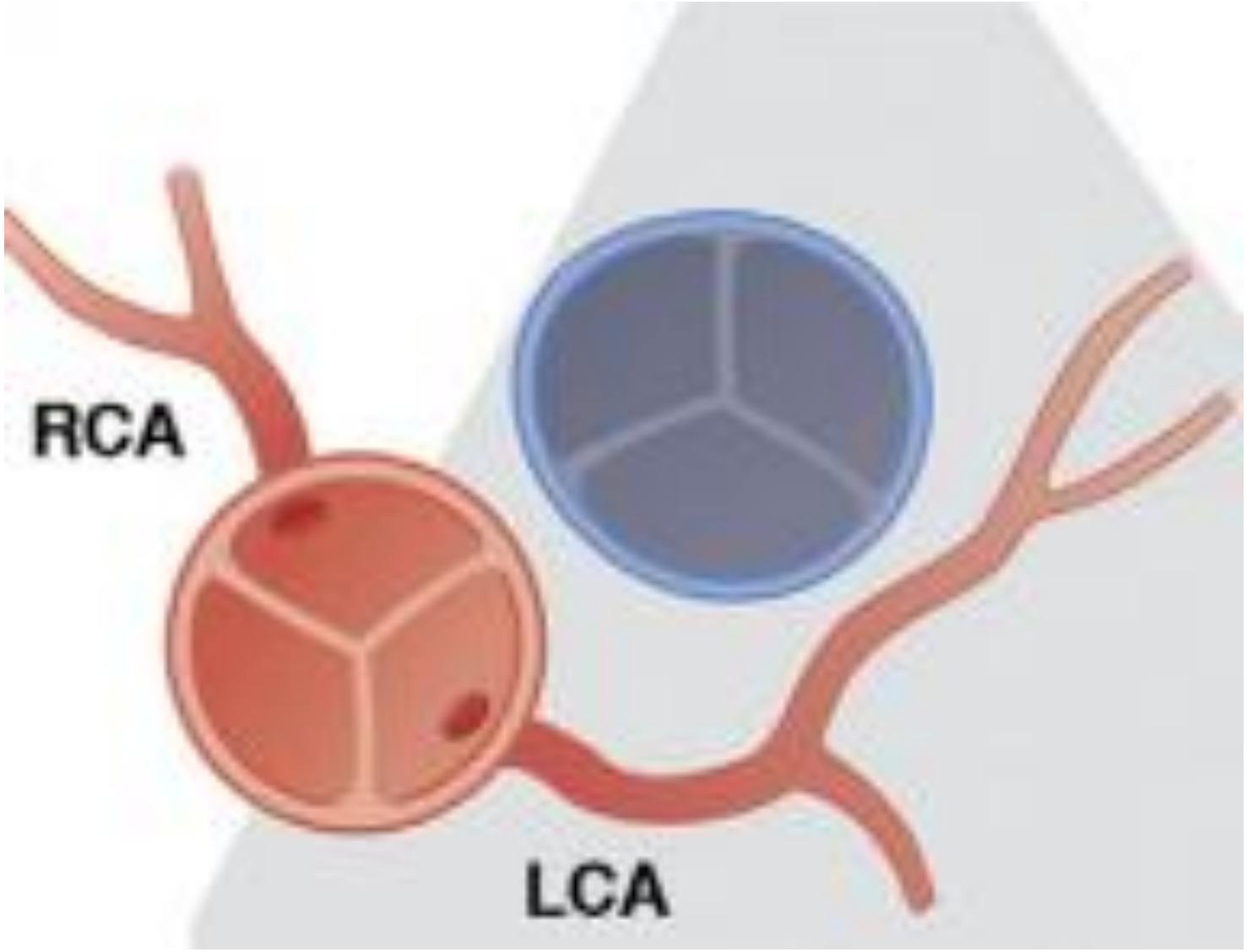
RCA
LCA

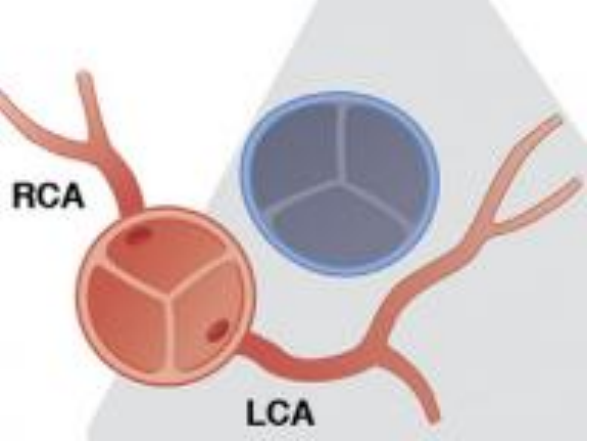
RCA
LCA

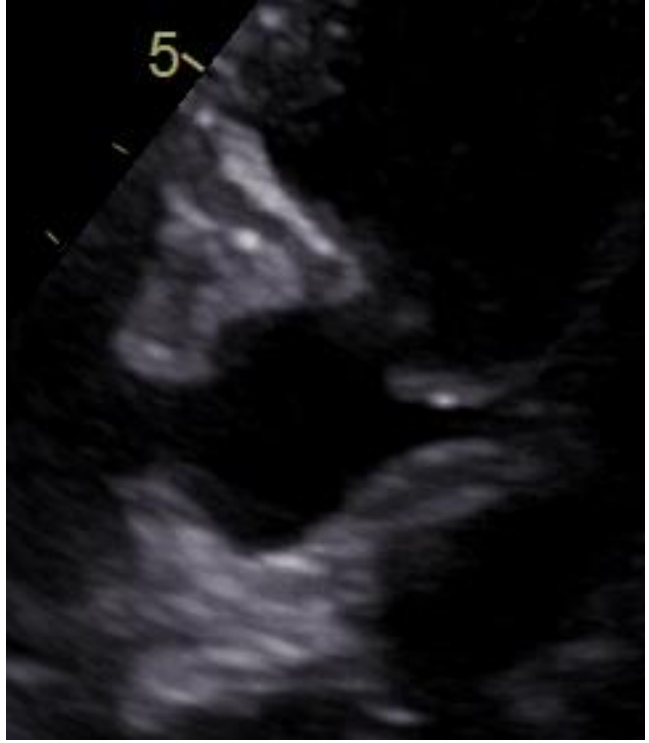
5

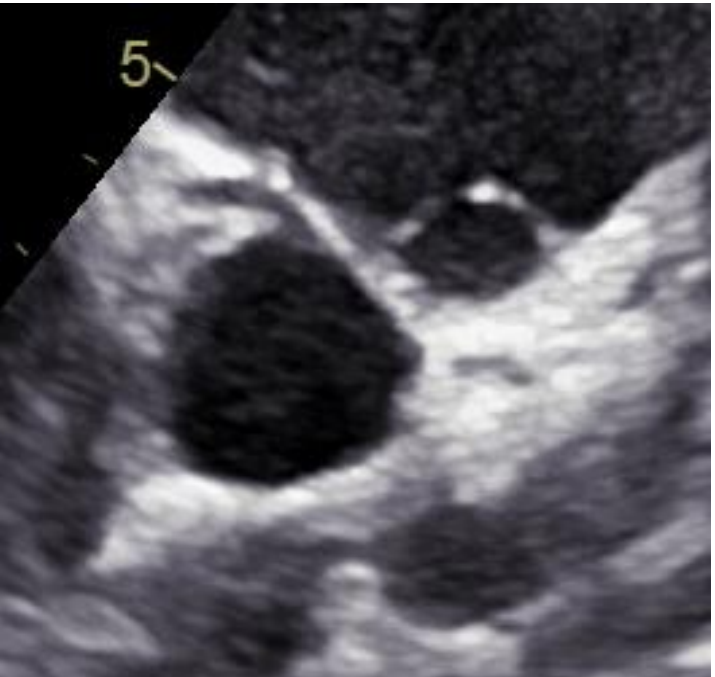
5

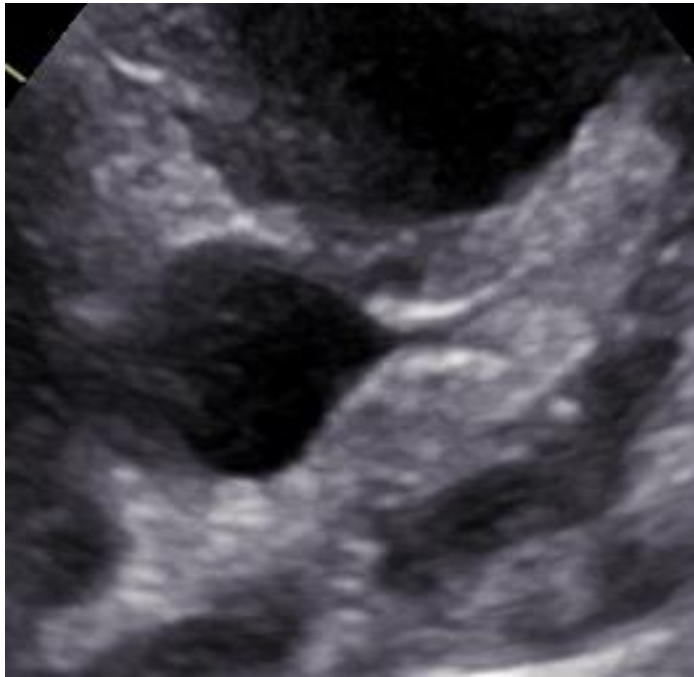

Limites de l'échographie

- Qualité des images
- Création d'images faussement rassurantes
- Sensibilité inconnue
- Différences inter-opérateurs
  (examens antérieurs jugés normaux)
- Multiplier les incidences
- Utiliser l'imagerie couleur (baisser les vitesses)
- **Multiplication par 10 du nombre de diagnostics**

Lorber R et al. J Am Coll Cardiol Img. 2015; 8: 1239-49.
Thankavel P et al. Pediatr Cardiol. 2015; 36: 120-5.

Imagerie couleur

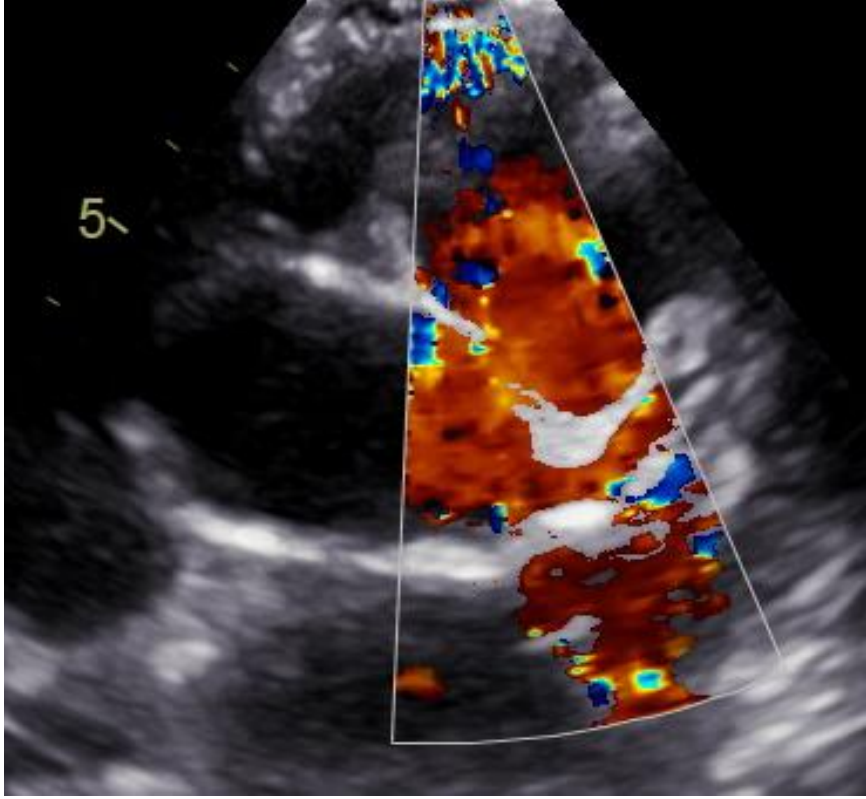

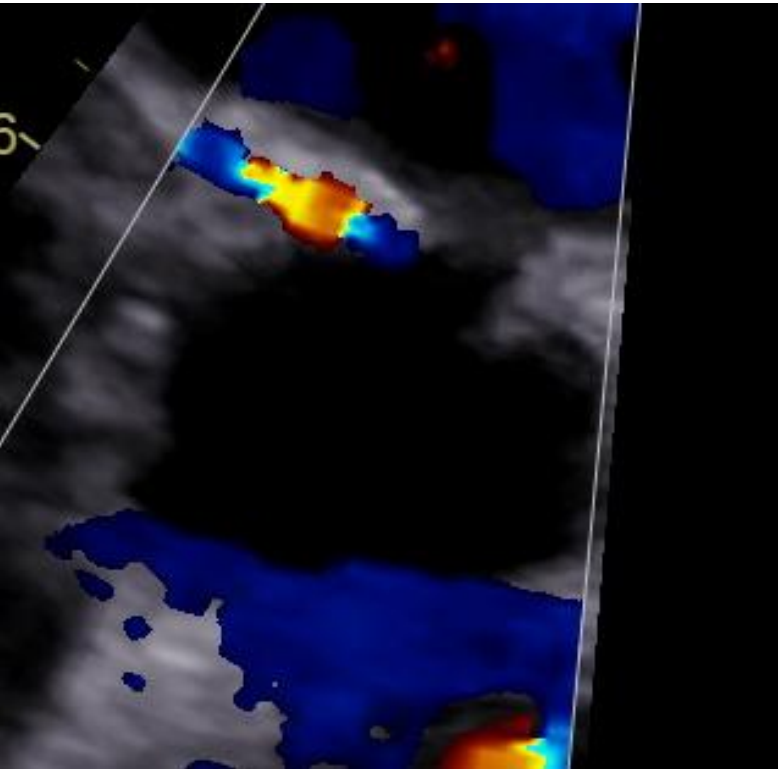

Imagerie couleur

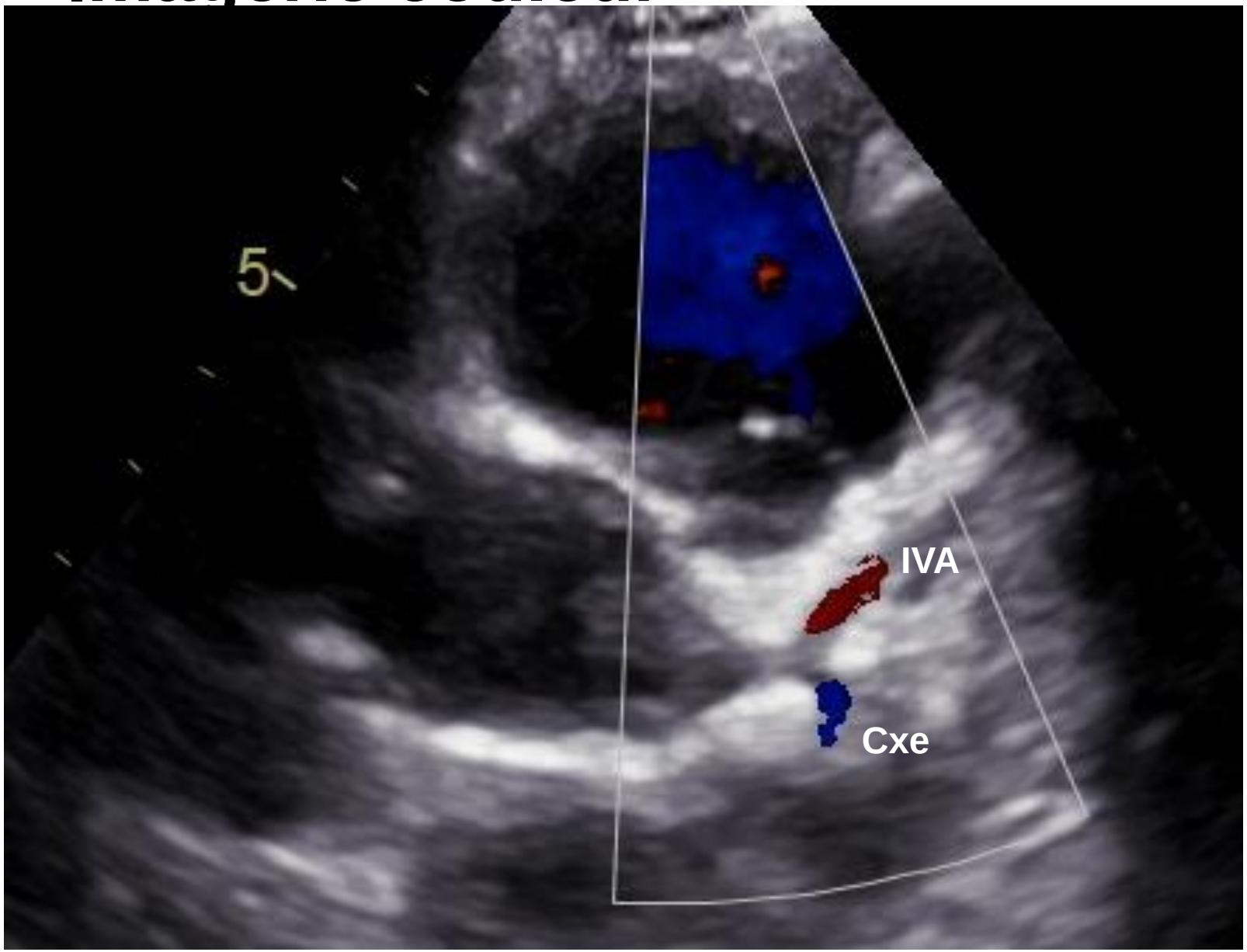

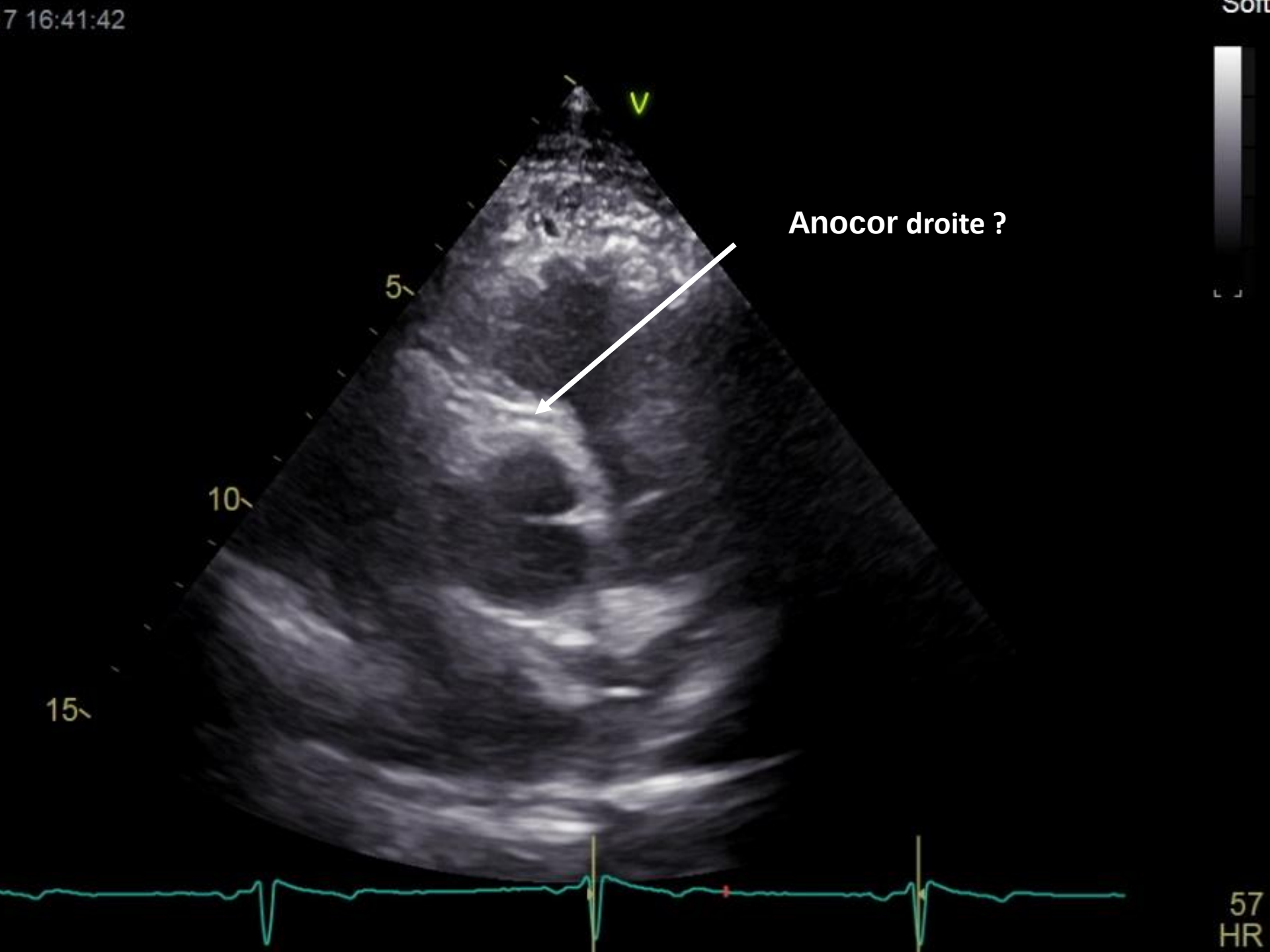
7 16:41:42
Anocor droite ?
5
10
15
57
HR

Enfant de 9 ans, dyspnée, précordialgies

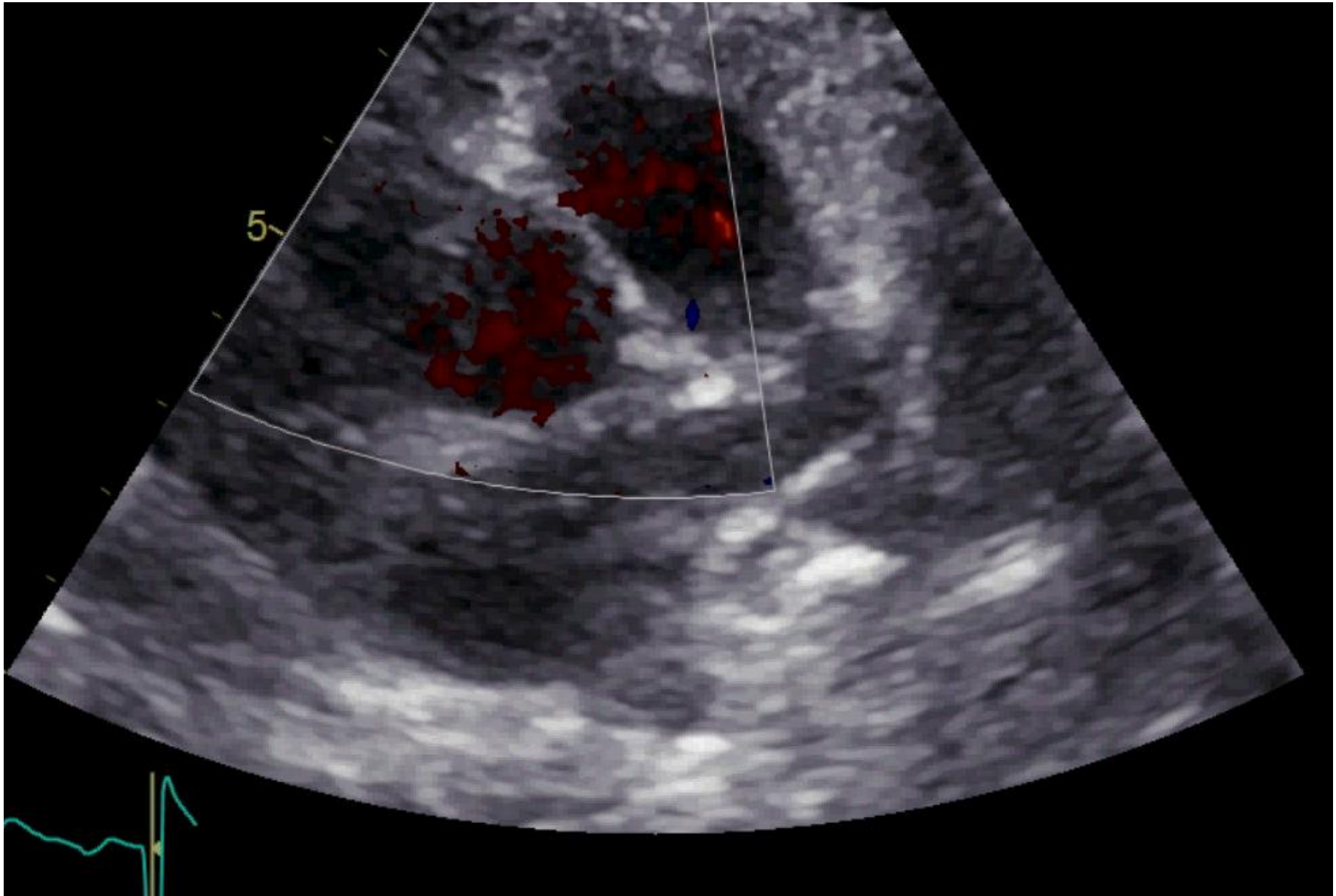

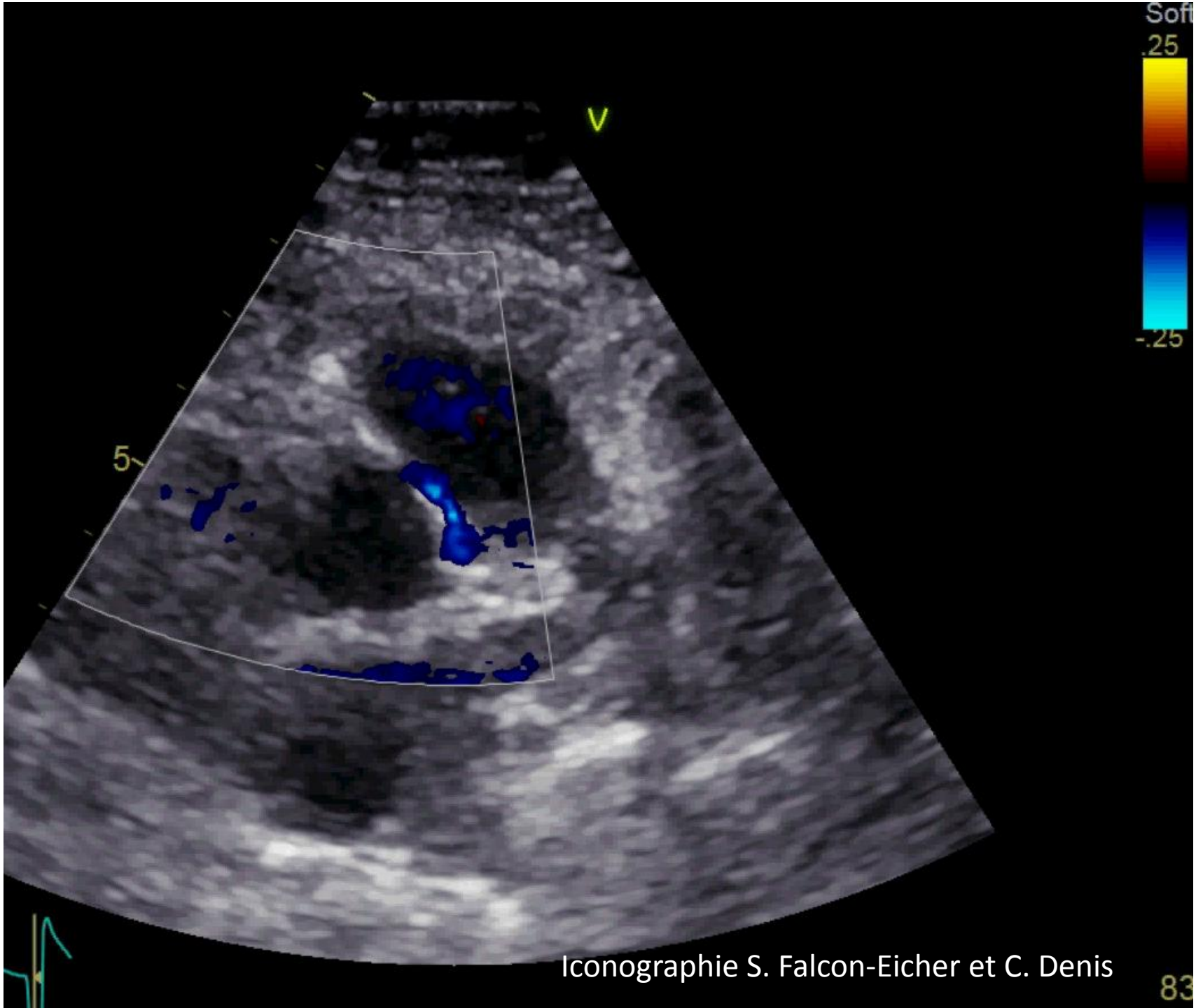

Iconographie S. Falcon-Eicher et C. Denis

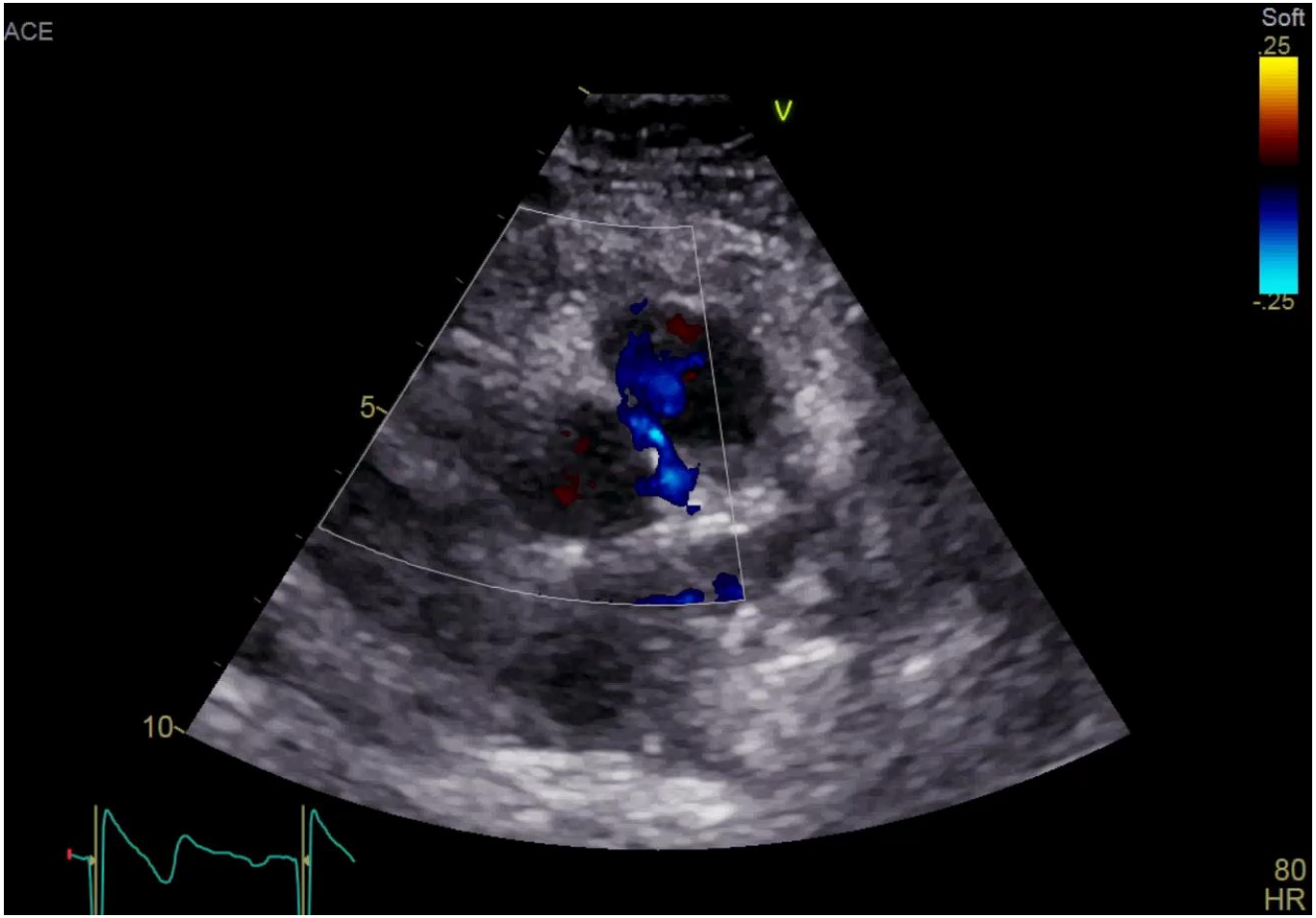
ACE
Soft
.25
-.25
V
5
10
80
HR

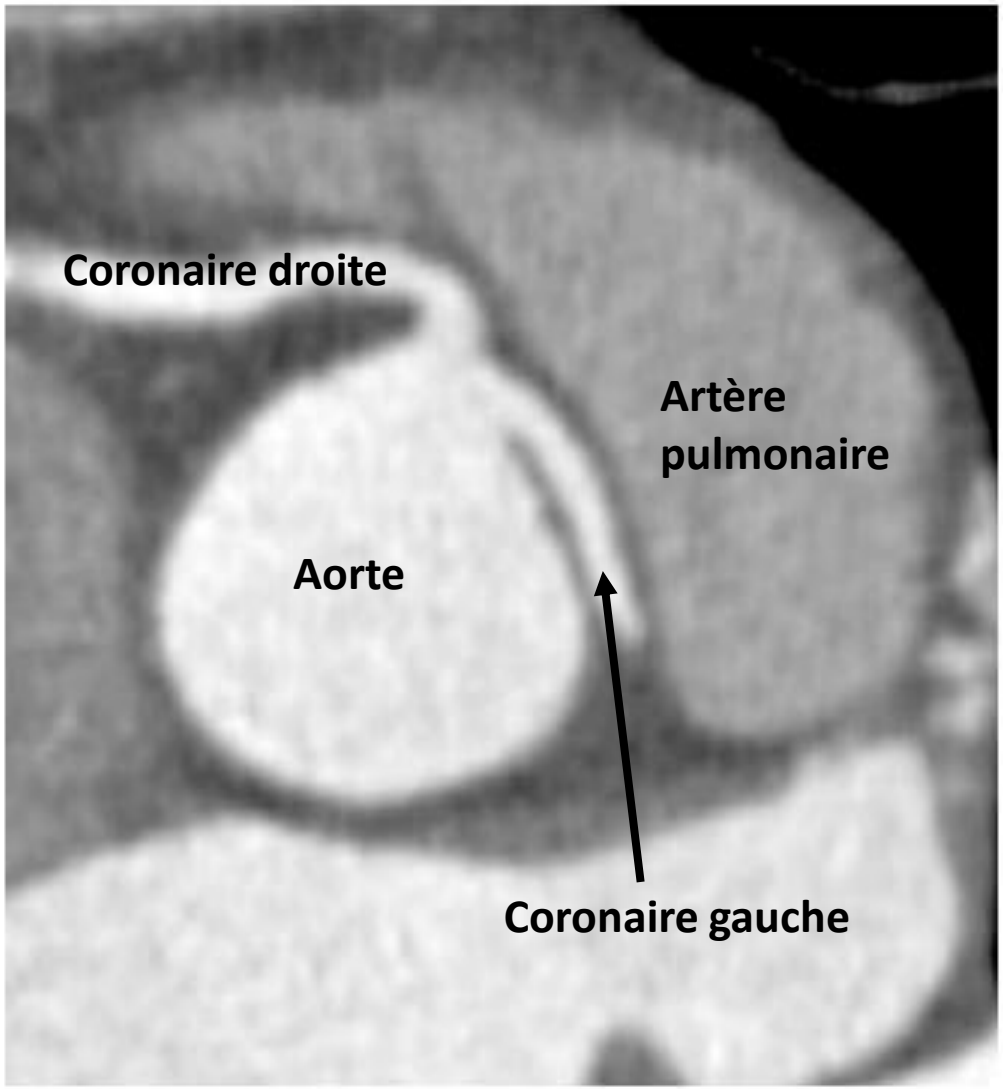

Iconographie adaptée d’après P. Aubry

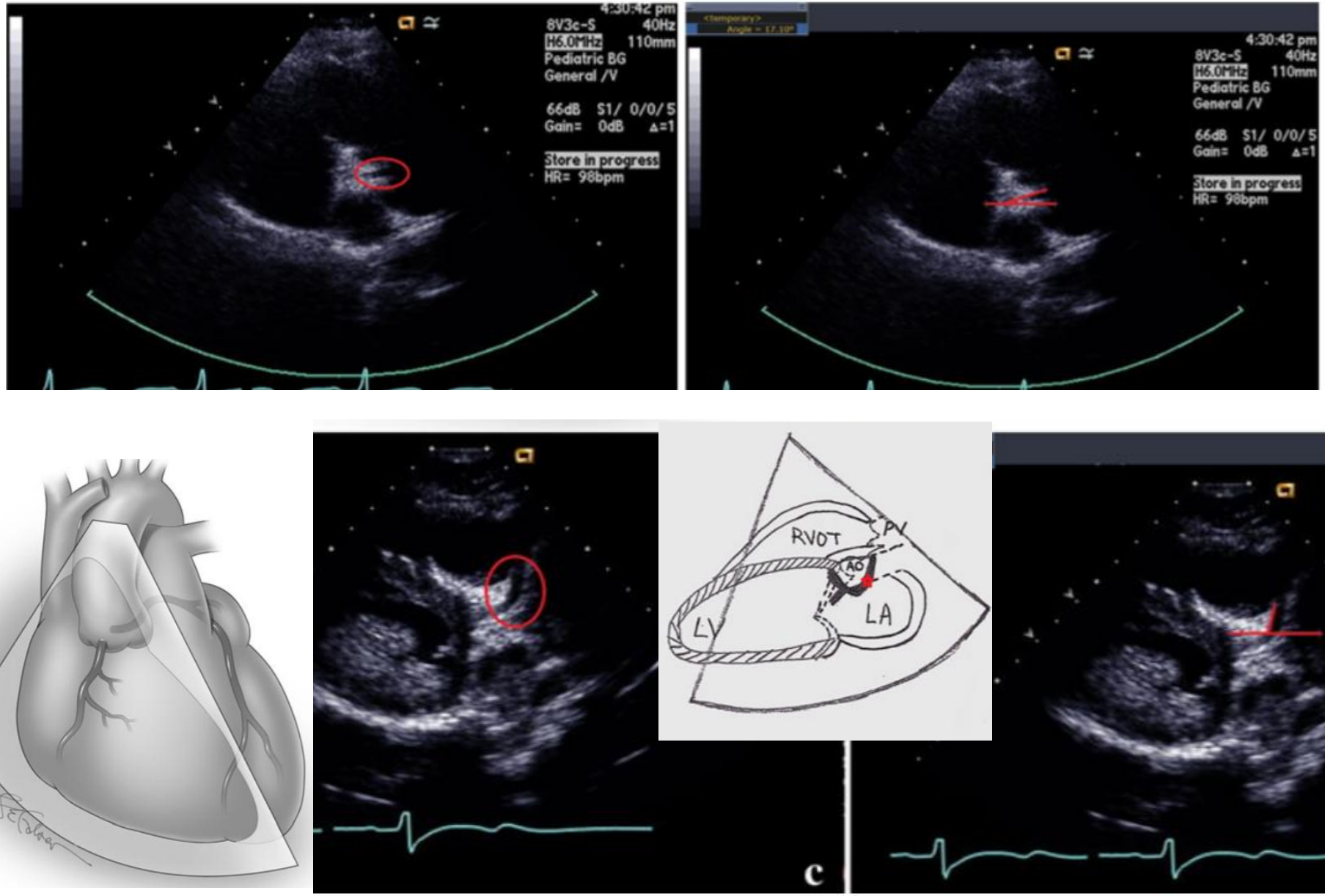

D'après Thankavel P et al. Pediatr Cardiol. 2013; 34: 842-6.

Footballeur 18 ans, centre de formation, asymptomatique

Footballeur 18 ans, centre de formation, asymptomatique

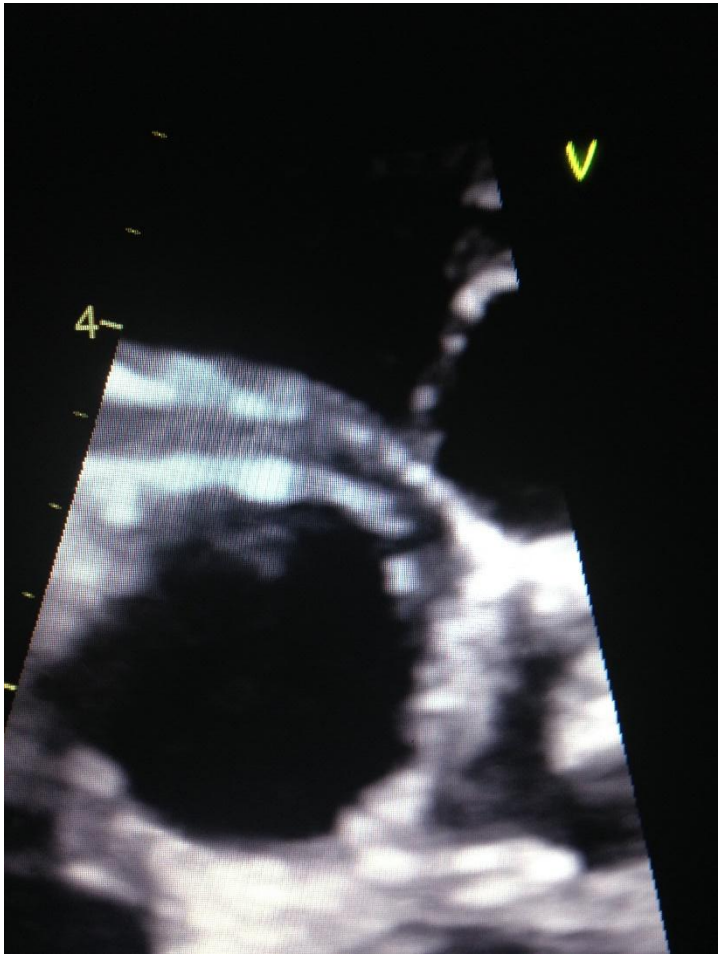

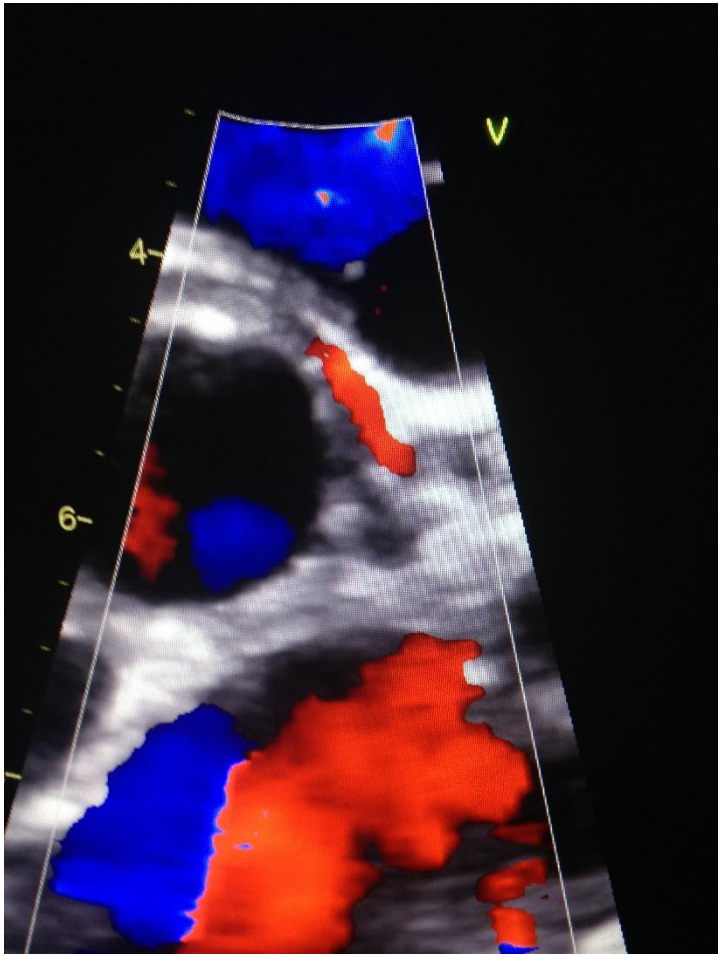
V
4
6

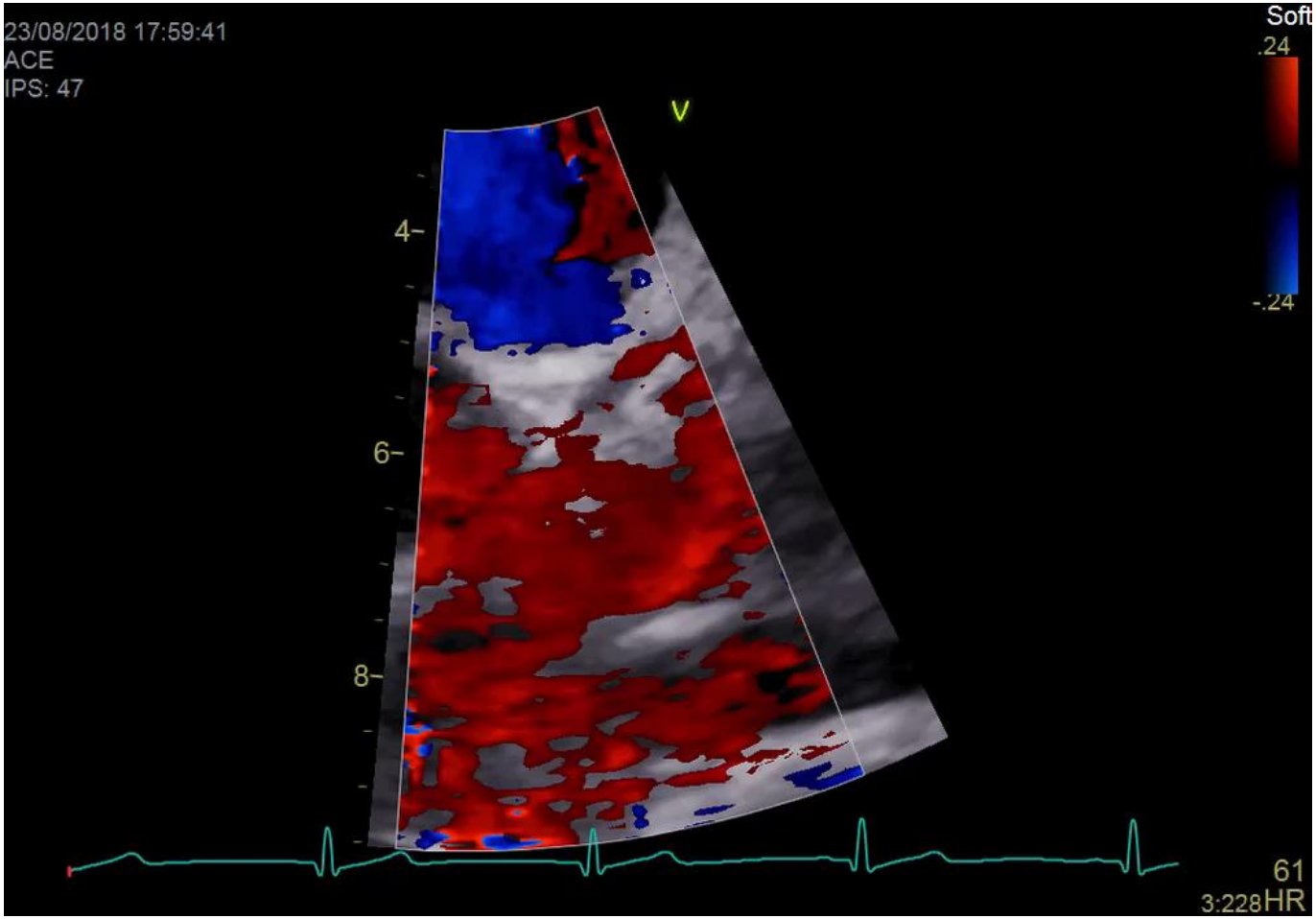
23/08/2018 17:59:41
ACE
IPS: 47
Soft
.24
-.24
V
4
6
8
61
3:228HR

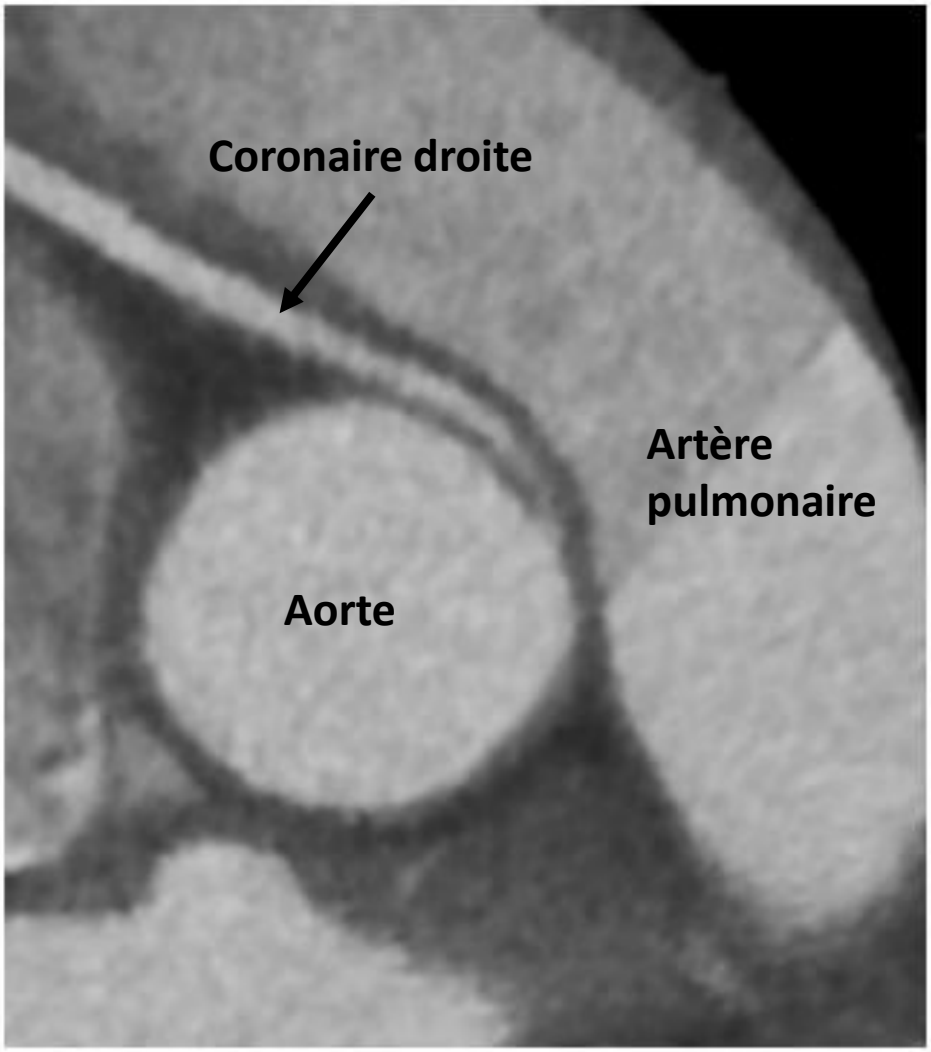

Iconographie adaptéed’après P. Aubry

Place des autres examens

- **Diagnostic**
  - Doute sur une image
  - Symptomatologie suspecte

- **Stratification du risque**
  - Morphologie
  - Ischémie

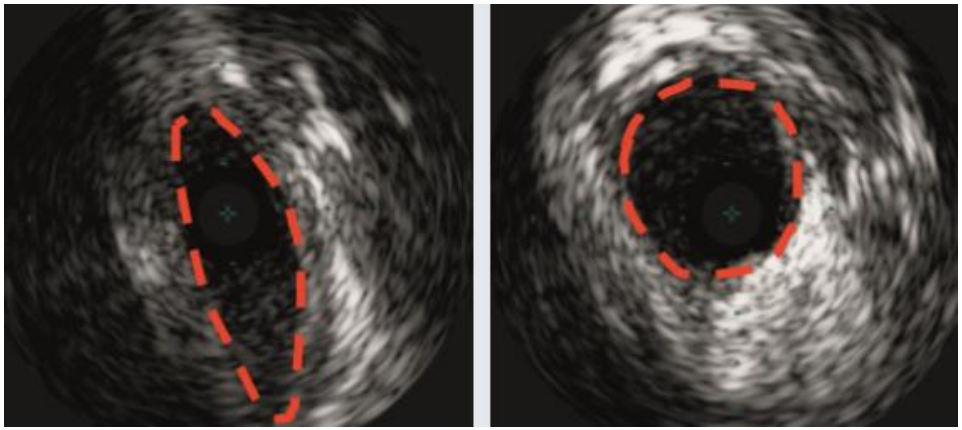

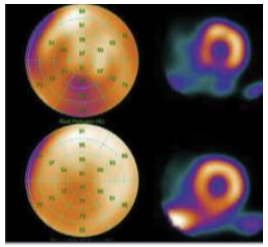

Iconographie d'après P. Aubry

En pratique

- **Décisions à prendre**
  - Attitude thérapeutique
  - Attitude quant à la pratique sportive

- **Recommandations récentes**
  - **Stout KK et al. J Am Coll Cardiol. 2019; 73: e81-192.**
  - **Van Hare GF et al. J Am Coll Cardiol. 2015; 66: 2372-84.**
  - **Borjesson M et al. Eur Heart J. 2019; 40: 13-18.**

- **Décision collégiale sur arguments anatomiques et fonctionnels en tenant compte du terrain (âge, sport)**

- **Même opéré, nécessité d'une surveillance**

Conclusions

- **Malformations « relativement » rares**
- **Risque extrêmement majoré par l'effort**
- **Dépistage possible par échographie**
  examen rigoureux
- **Scanner voire IRM en cas de doute**
- **Incertitudes sur l'histoire naturelle :**
  Intérêt des registres (ANOCOR)